

# Endocrine I Laboratory Exercises

Objectives: Students will work in teams or individually to apply the following specific concepts from the Endocrine I lecture as they practice identifying histological images:

1. Pituitary anatomy and proximity to vital structures.
2. Pituitary embryology and origin of each lobe.
3. The consequences of loss of input from the hypothalamus to the pituitary
4. The consequences of tumor formation in the anterior pituitary and how one would detect the cell type involved.
5. Structure and function of the thyroid and parathyroid glands.

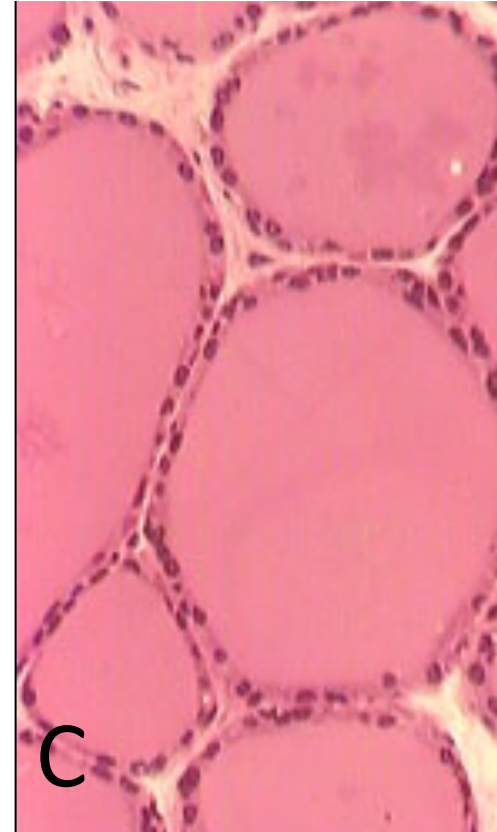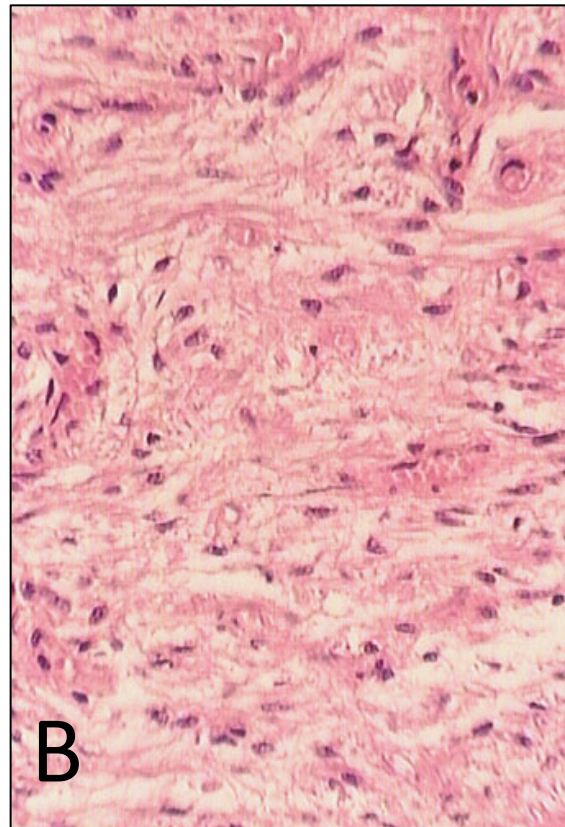
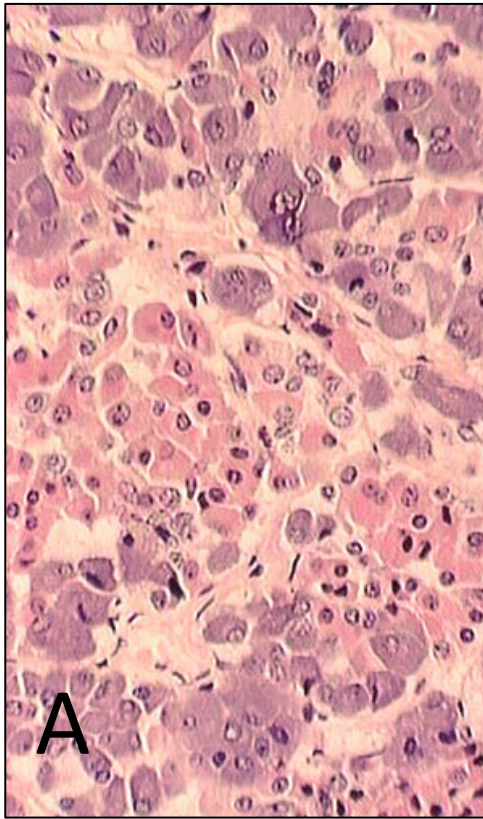
# Case 1. “I can’t see my computer screen”

Mathew James, age 31, is a computer programmer. He went to his optometrist because he noted that he could not see his computer screen completely. The optician reported a bitemporal hemianopsia. He had always been a serious athlete, but his abilities began to deteriorate gradually, despite the attentions of his personal trainer. The optician referred him to an endocrinologist.

Here is what he saw when looking out a window.



**Why was he referred to an endocrinologist? Discuss for 2 minutes. What anatomical structures are involved?**



On examination, he was found to be grossly hypothyroid and hypogonadal as confirmed using biochemical tests that provided the following results:

Serum free-Thyroxine ( $T_4$ ) **4 pmol/l** (NR 10–24 pmol/l)

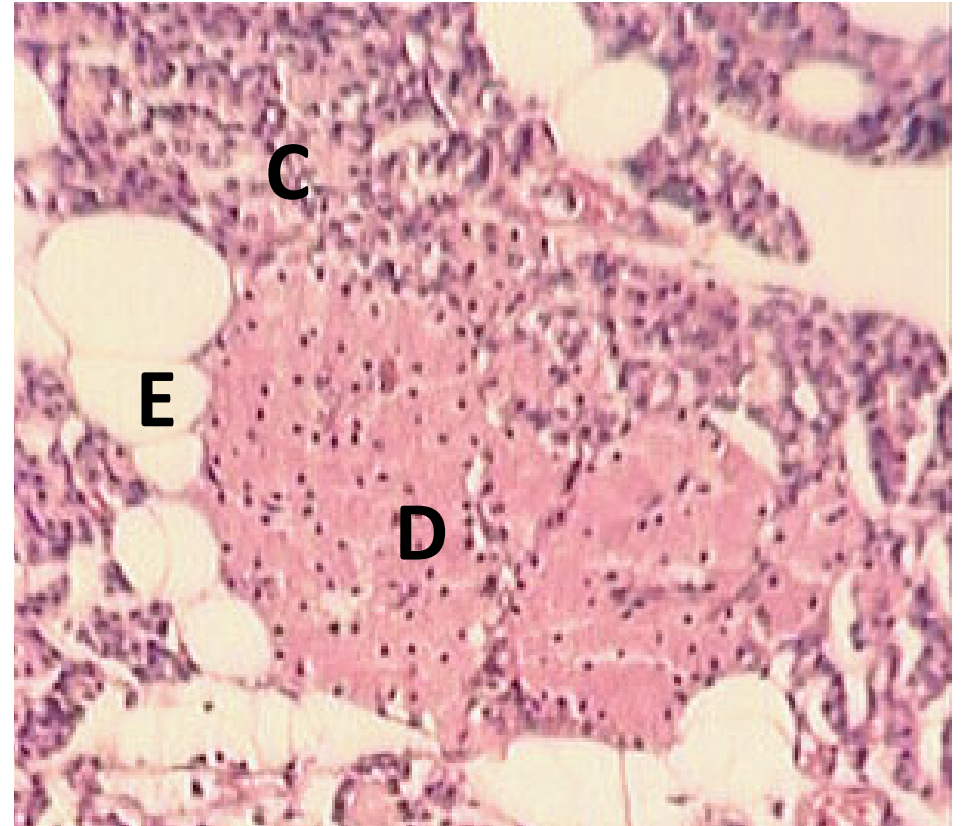
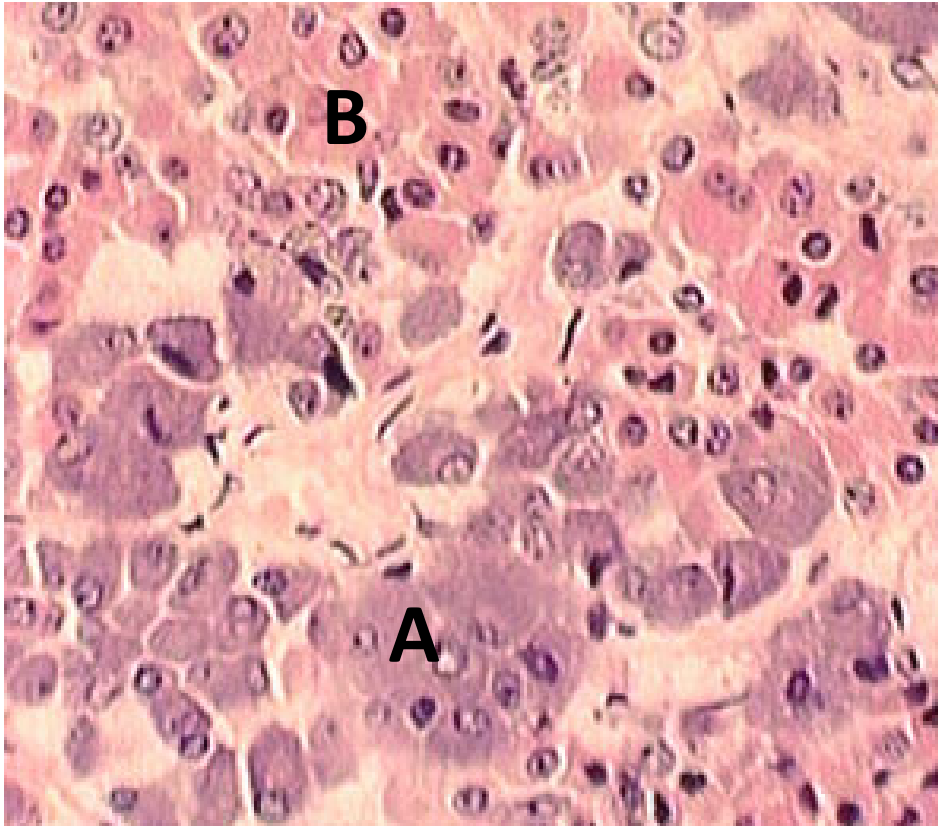
TSH **0.9 mU/l** (NR 0.5–4.0 mU/l)

Testosterone **<0.5 nmol/l** (NR 9–25 nmol/l)

Take **5 minutes** to study the sections above, and identify each organ or region of the organ from which the section was taken. Use Histology Times.

1. Based on the serum values and symptoms, where are the affected cells?
2. You suspect a tumor, but where might it be located?

**A only; B only; C only; A and B; A and C; B and C**



Take **5 minutes** to identify each of the 5 cell types indicated by the letters above.

Considering his hypothyroid and hypogonadal conditions and serum hormone levels, which cell type(s) might have been compromised?

**A. B. C. D. E.**



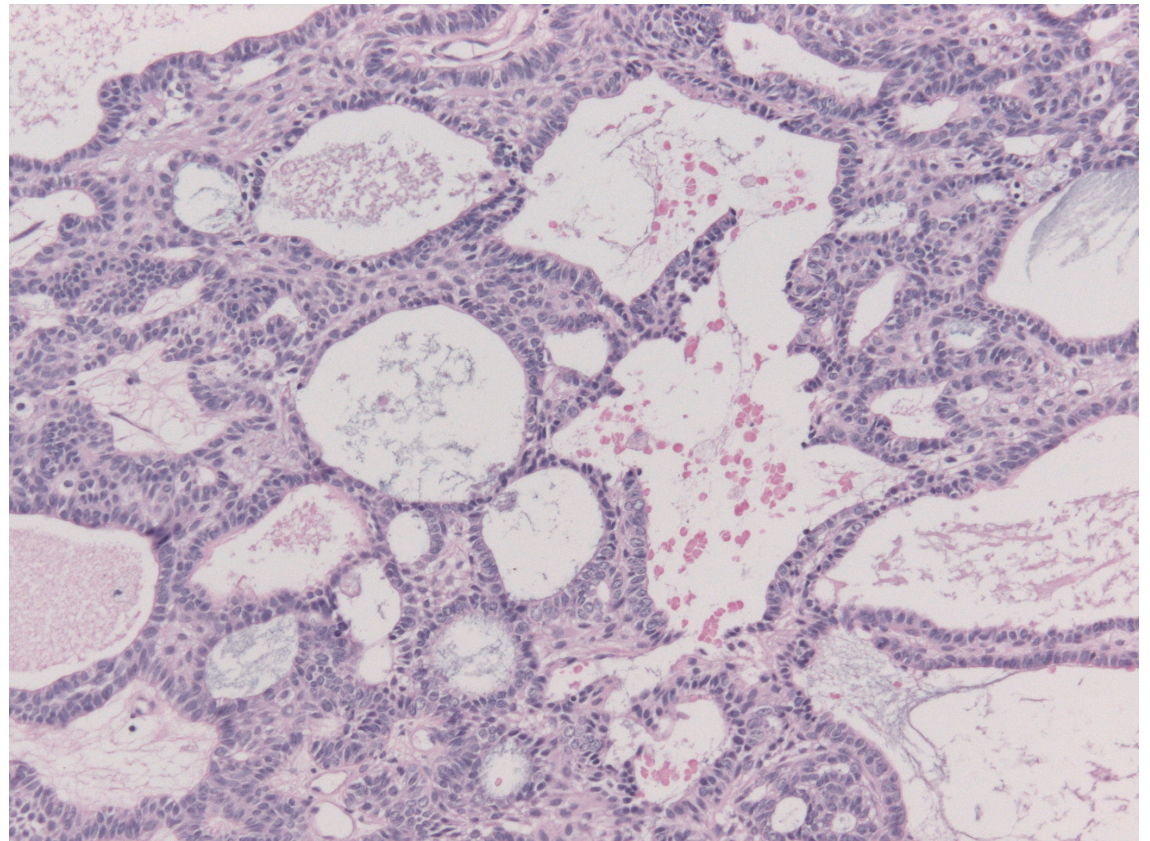
Take **2 minutes** to discuss thyroid follicular cells during hypothyroidism. Considering his serum values, you would expect his thyroid cells to have:

- A. Transitioned to tall columnar
- B. Remained cuboidal-columnar
- C. Become more low cuboidal-squamous
- D. Become stratified cuboidal
- E. Become stratified squamous

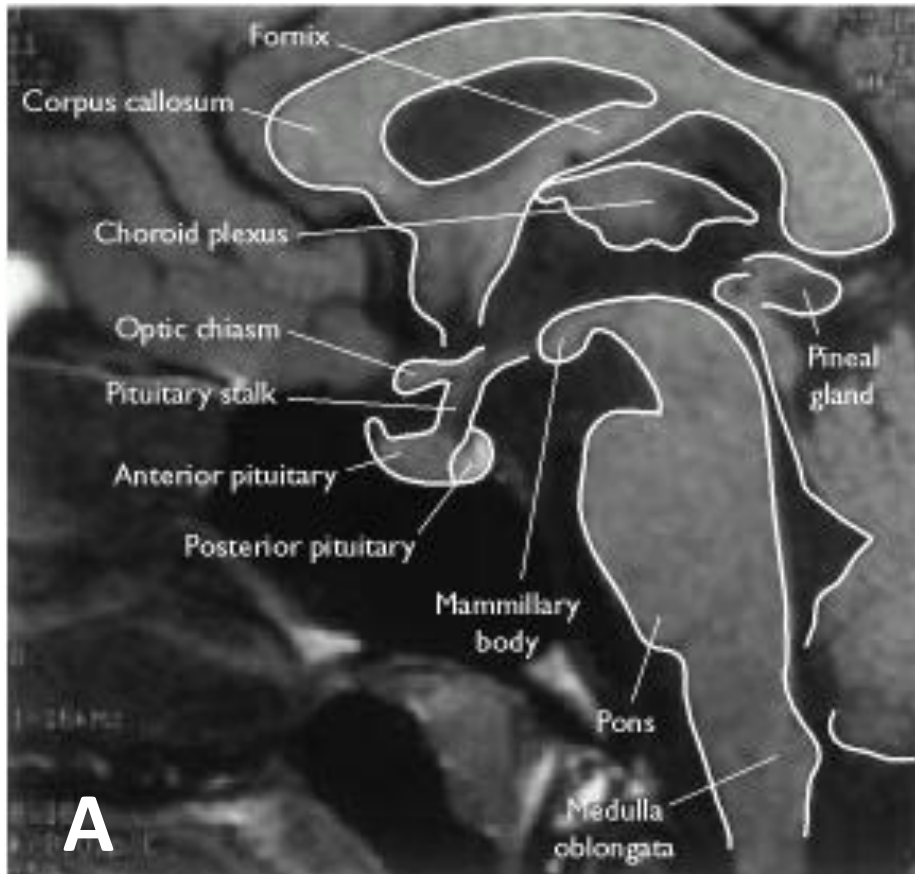
Mr. James' MRI scan showed a large suprasellar tumor that was removed by transsphenoidal surgery. Histologically, it was reported to be a craniopharyngioma as pictured:

**Discuss with your team the following questions:**

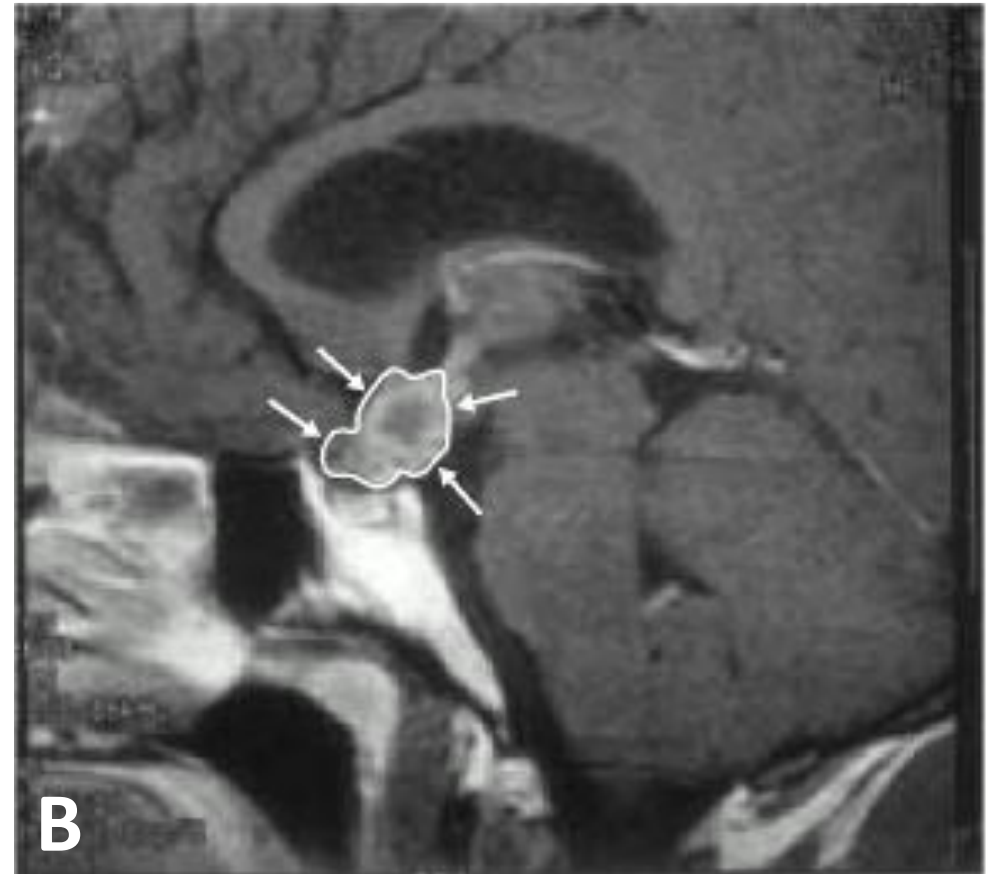
- 1) What does suprasellar mean?
- 2) What is the significance of the root words "cranio" and "pharyngioma" with respect to the origin of this tumor.



**Take 5 minutes to discuss this slide and the next two slides and to answer the questions.**



**Normal Pituitary and Hypothalamus**



**Craniopharyngioma**

Evaluate these two MRIs and find all structures relevant to the case.

Compare the normal anatomy to the craniopharyngioma.

Would you expect that other functions might be compromised by the tumor? If so, what are they?

The origin of a craniopharyngioma is related to the residual cells left from embryonic development because the:

- A. adenohypophysis originates from the pharynx
- B. posterior lobe originates from the pharynx
- C. adenohypophysis contains cells that migrate from the neural crest
- D. diencephalon originates from the roof of the mouth (oral pharynx)
- E. neurohypophysis originates from the diencephalon

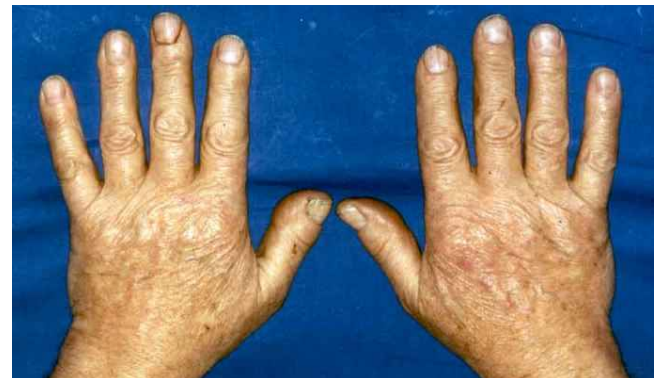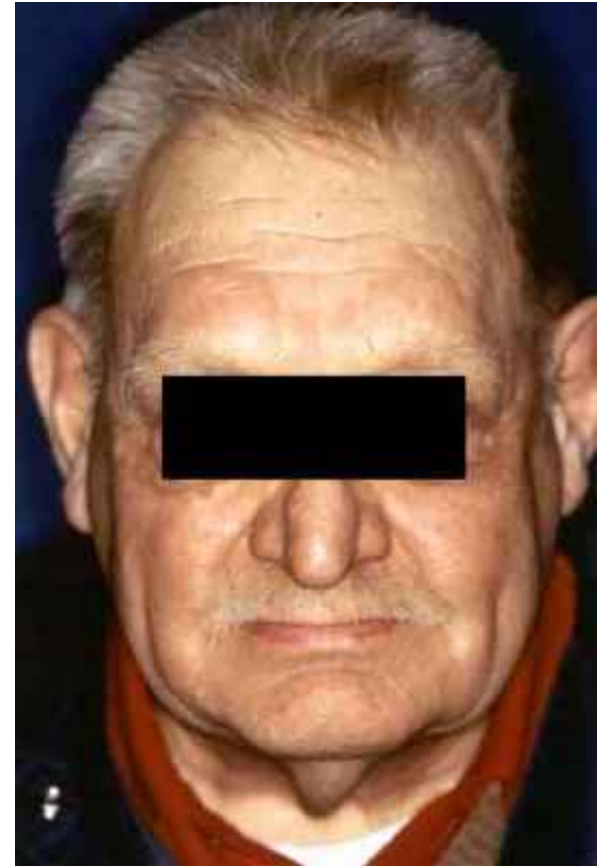


# Case 2: My hands are numb!

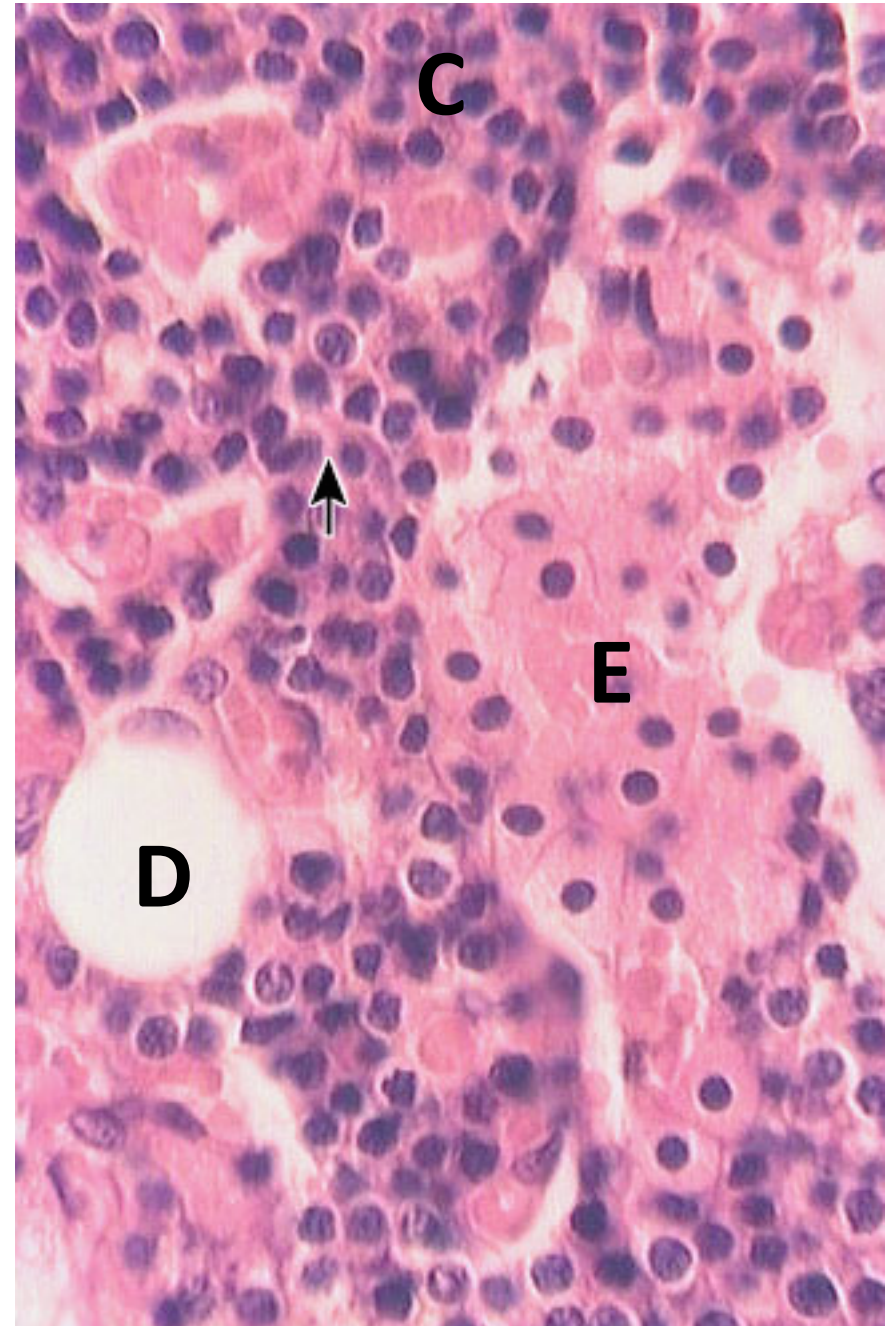
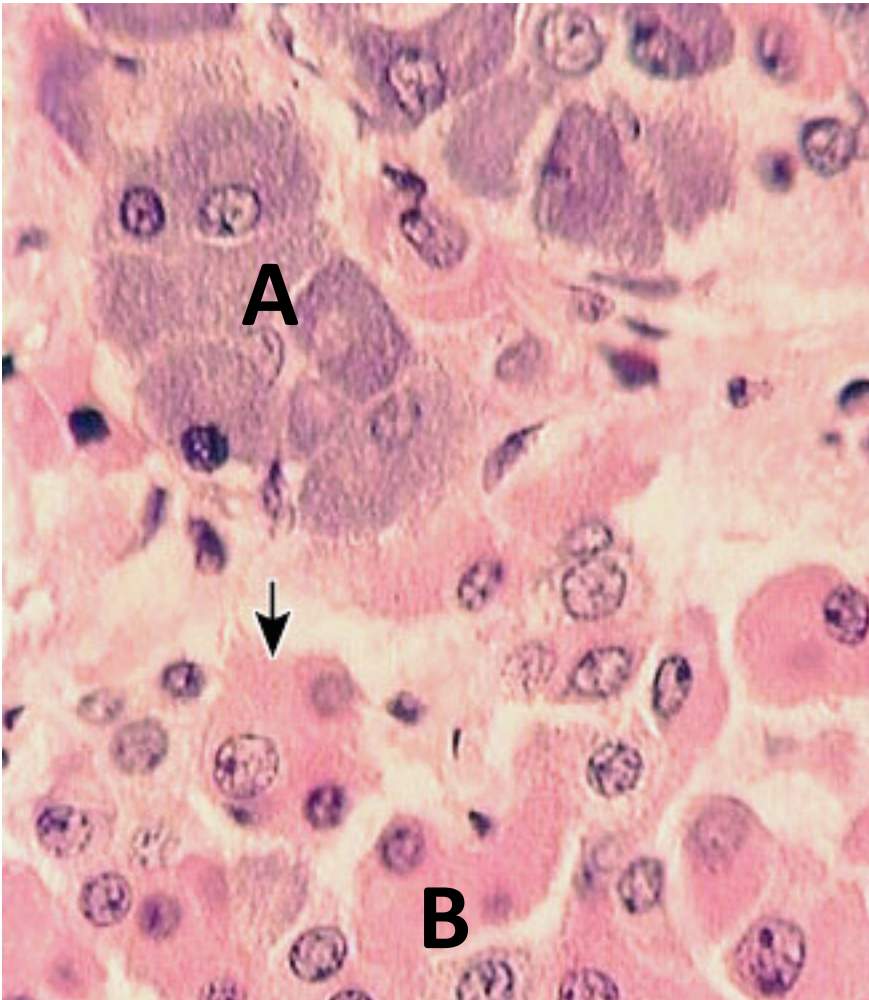Mr. Hyde, a 58-year-old carpenter, was seen in the orthopedic clinic as he repeatedly felt “pins and needles” and numbness in both hands. The orthopedic surgeon confirmed the clinical diagnosis of bilateral carpal tunnel syndrome and performed bilateral decompression of the median nerve at the wrist. However the surgeon also noted that the hands were broad and spatulate and referred him to the Endocrine Outpatient Clinic.

Take **5 minutes** and discuss this slide and the next slide.

What should be done next? What serum hormones would you assay?





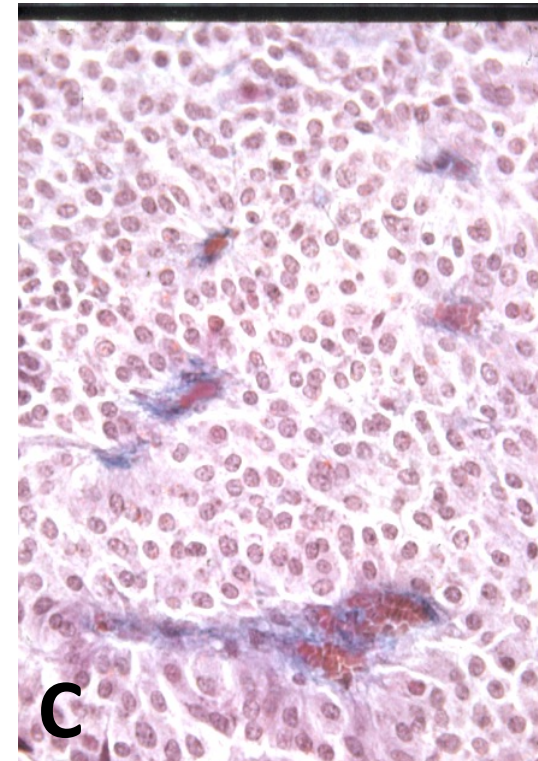
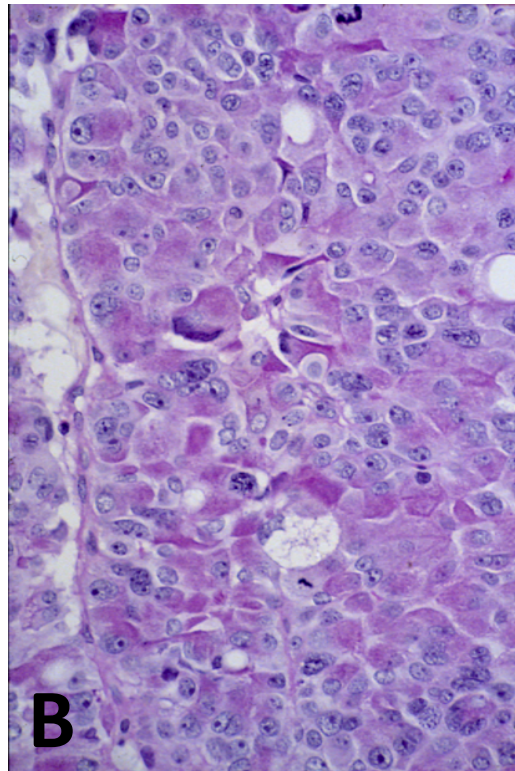
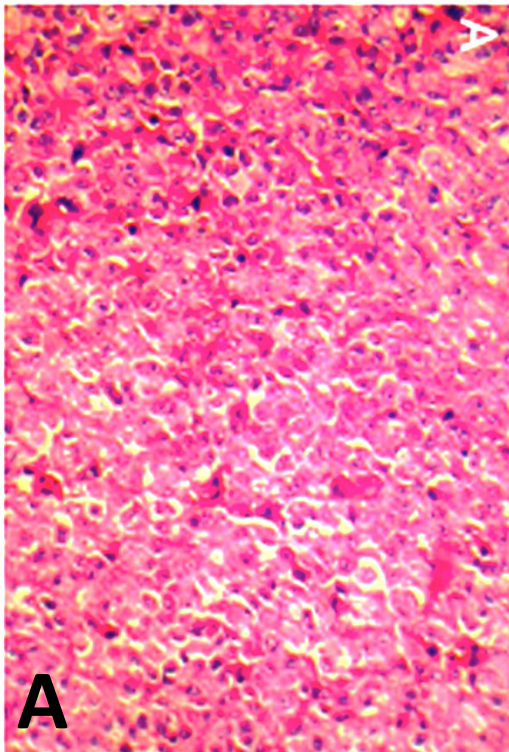


Based on evidence thus far, which cell type might be dysfunctional?

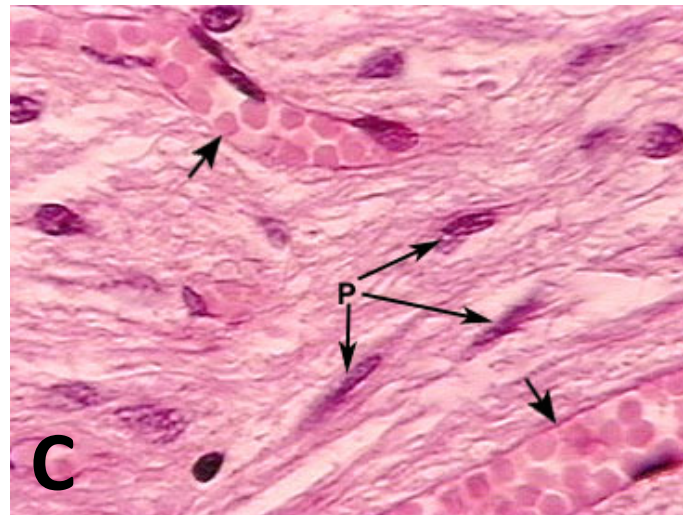
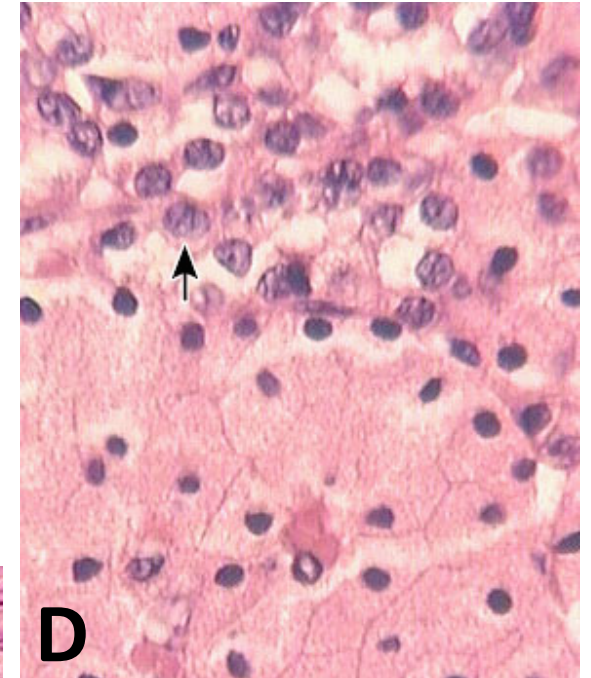
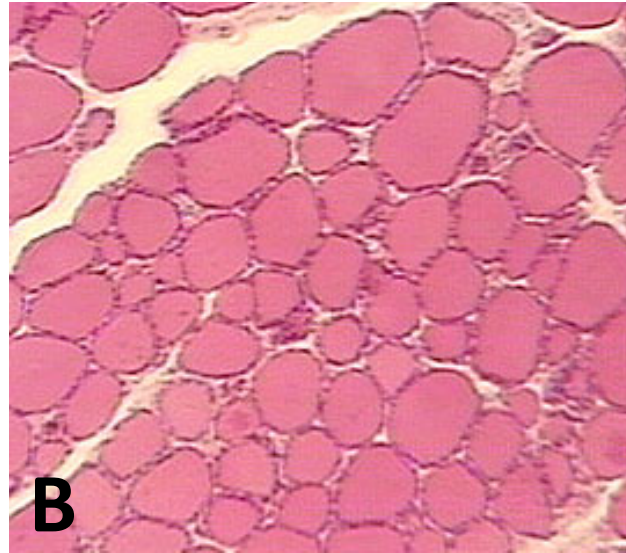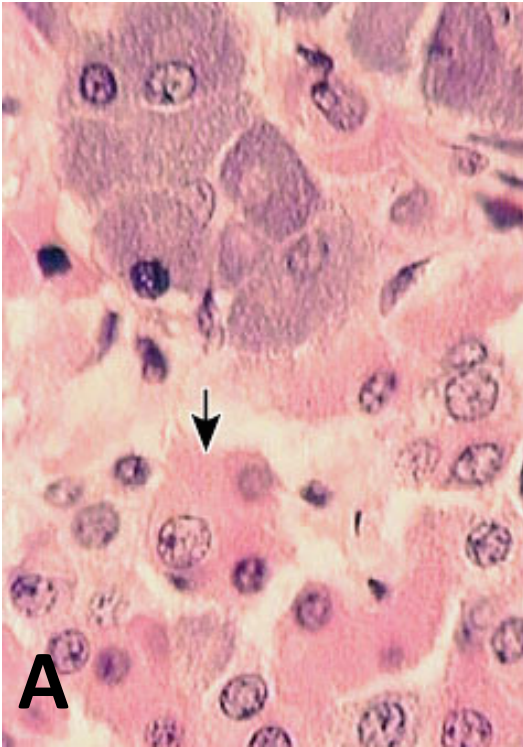**A., B., C., D., E.**



At the Endocrine clinic, they did an oral glucose tolerance test and measured growth hormone. GH levels were more than 90 mU/l and after an oral glucose load, there was no reduction in GH (normally GH levels would be reduced to 1-2 mU/l.), indicating lack of normal control of GH secretion. Take **2 minutes** to study the sections below and to answer this question: Chemotherapy for GH-secreting tumors is octreotide (an analog of somatostatin), which would be expected to shrink which of the following tumors?







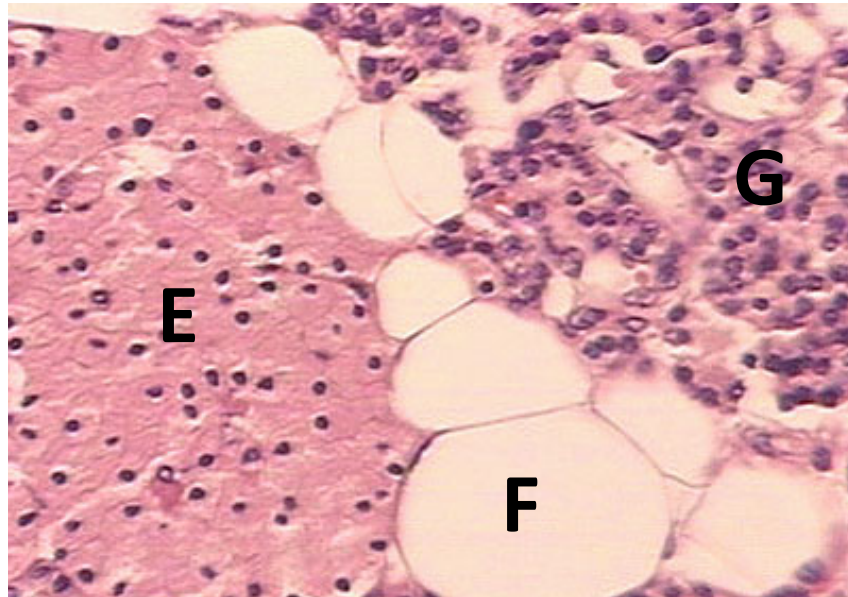
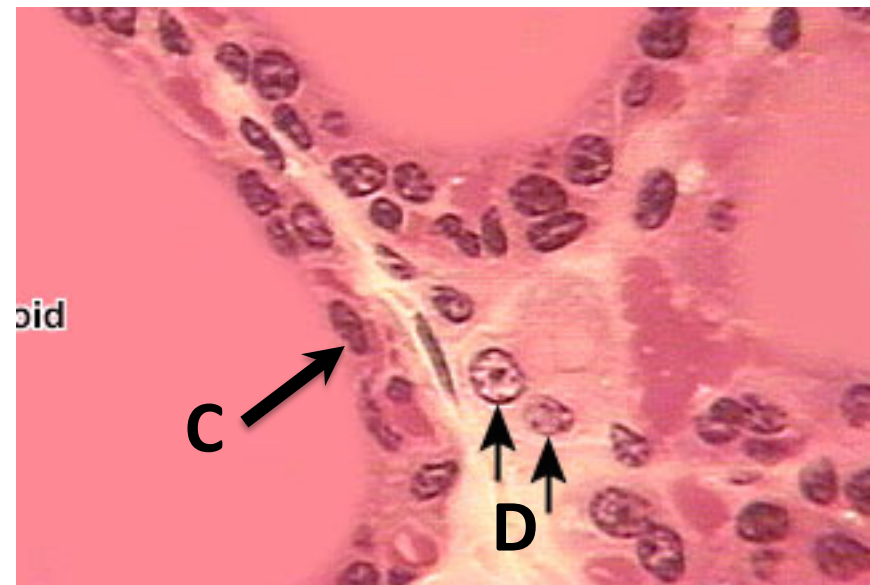
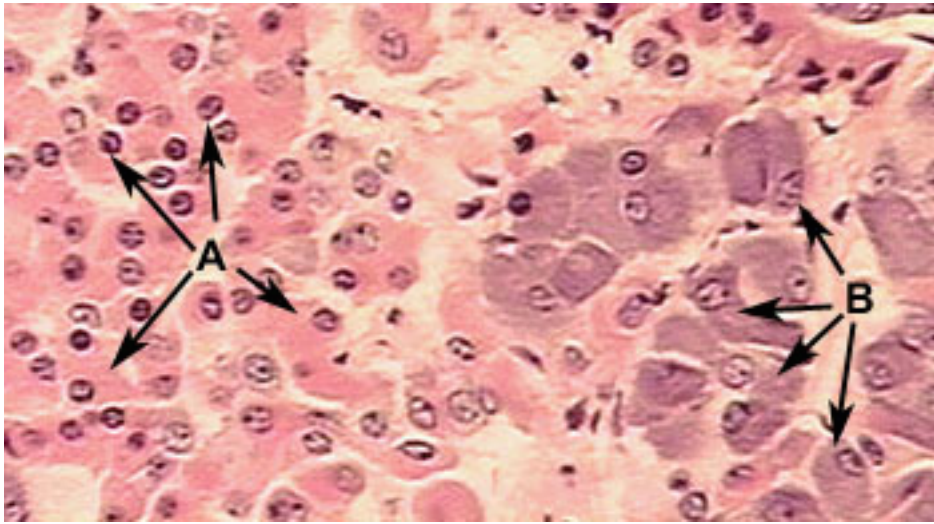
**From what region of which endocrine organ were these sections taken?**

**HORMONE CHOICES:**

- A. Oxytocin
- B. Luteinizing hormone
- C. Thyroxine
- D. Prolactin
- E. Parathyroid hormone

Identify the regions—**5 minutes**. Your patient has a lesion in the hypothalamus that has destroyed fibers that run in the tract that supplies the pars nervosa. She becomes pregnant, but labor does not progress normally without hormonal treatment. She produces milk, but is unable to lactate. From these symptoms, you suggest that the lesion has affected the secretion of \_\_\_\_\_ hormone from which organ/region\_\_\_\_\_.





Discuss and identify—**5 minutes**  
 Your Golden Retriever just had a litter of 14 pups. You take her to the vet because she is “shaking”. The vet explains that she has tetany because of low serum calcium and possible under-function of which of the above cell types: **A., B., C., D., E., F., G.**

Identify the hormone that is low: **A. Prolactin B. Oxytocin C. Parathyroid hormone, D. Calcitonin, E. Vasopressin**